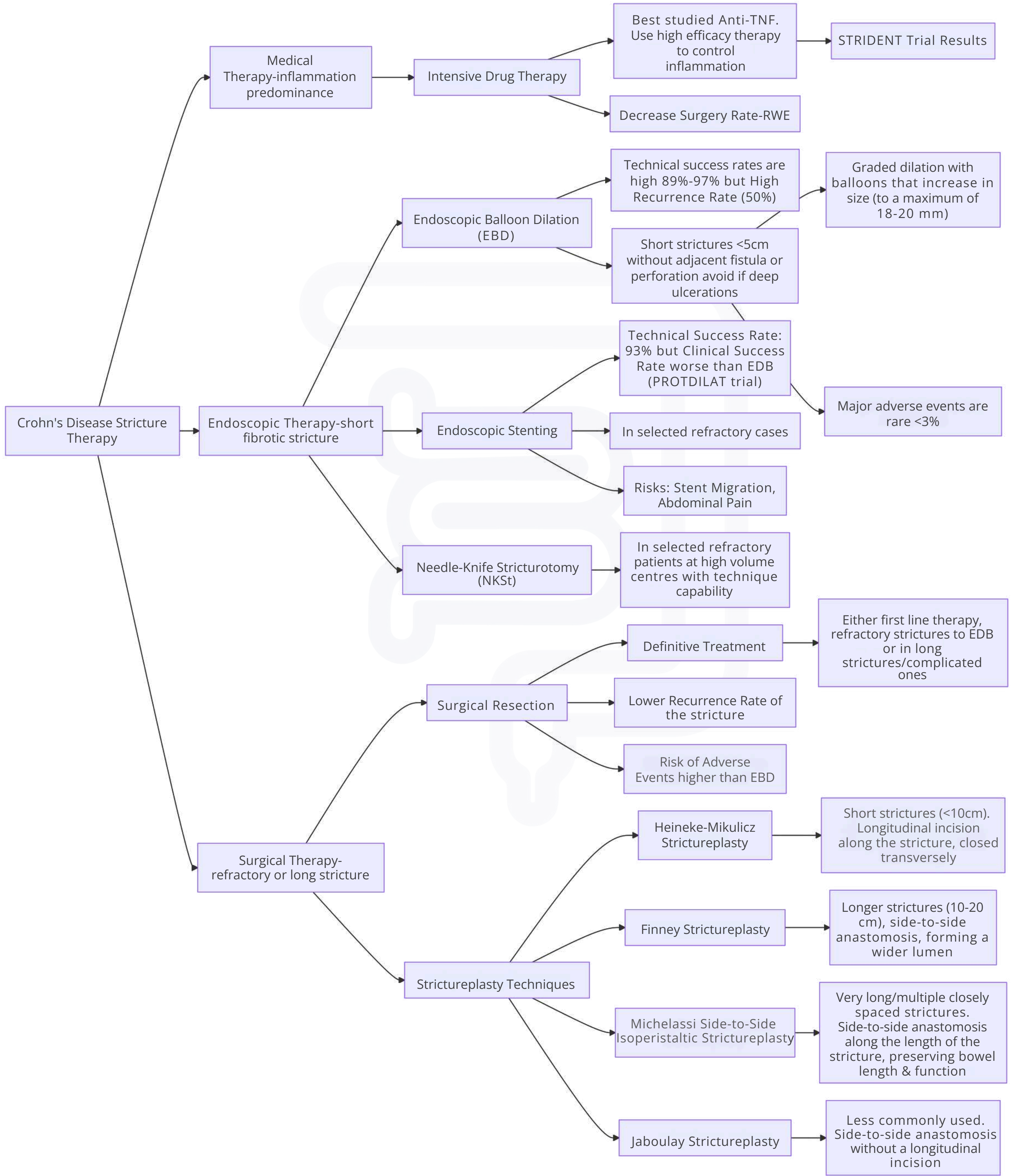


Crohn's disease stricture approach



This diagram is based on a combination of trial results, surgical and endoscopic consensus, and does not reflect the personal opinion of the author. Please note that each case should be individualized and discussed in multidisciplinary meetings. Additionally, colonic strictures are not managed with strictureplasty, and certain techniques may require adaptation depending on factors such as stricture length and characteristics, disease behavior, patient-specific considerations, and institutional expertise. This diagram is for informational purposes only and should not be considered a substitute for clinical judgment or professional medical advice.

