

# ROBARTS HISTOPATHOLOGICAL INDEX

---

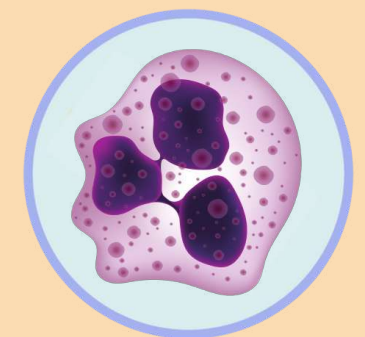**RHI= 1 x chronic inflammatory infiltrate level + 2 x lamina propria neutrophils + 3x neutrophils in epithelium + 5x erosion or ulceration**

## CHRONIC INFLAMMATORY INFILTRATE

- 0 No infiltrate
- 1 Mild but unequivocal increase
- 2 Moderate increase
- 3 Marked increase

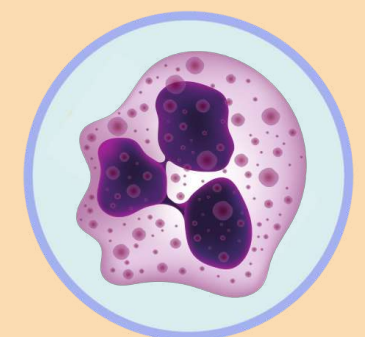
## LAMINA PROPIA NEUTROPHILS

- 0 None
- 1 Mild but unequivocal increase
- 2 Moderate increase
- 3 Marked increase



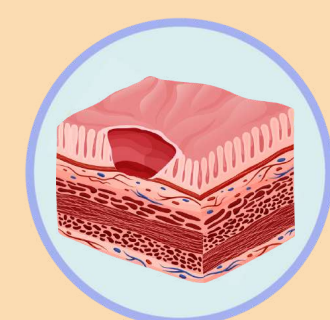
## NEUTROPHILS IN EPITHELIUM

- 0 None
- 1 <5% of the crypt involved
- 2 <50% of the crypt involved
- 3 >50% of the crypt involved



## EROSIONS OR ULCERATION

- 0 No erosion/ulceration/granulation tissue
- 1 Recovering epithelium+adjacent inflammation
- 1 Probable erosion focally stripped
- 2 Unequivocal erosion
- 3 Ulcer or granulation tissue



# ROBARTS HISTOLOGICAL INDEX

---

## GRADE

**RHI = 1 x chronic inflammatory infiltrate level + 2 x lamina propria neutrophils + 3x neutrophils in epithelium + 5x erosion or ulceration**

The total score ranges from 0 (no disease activity) to 33 (severe disease activity).

