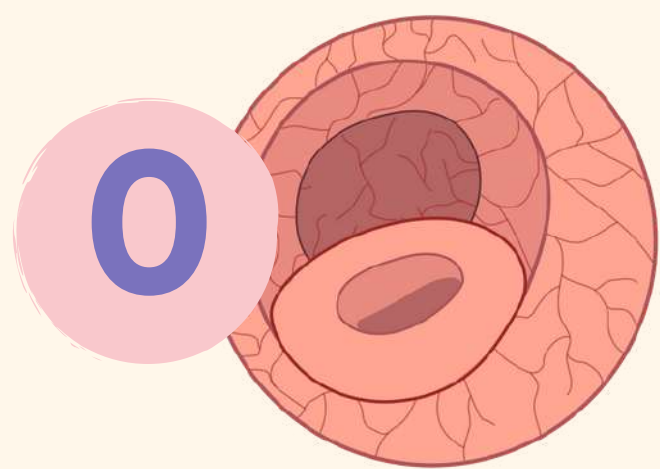
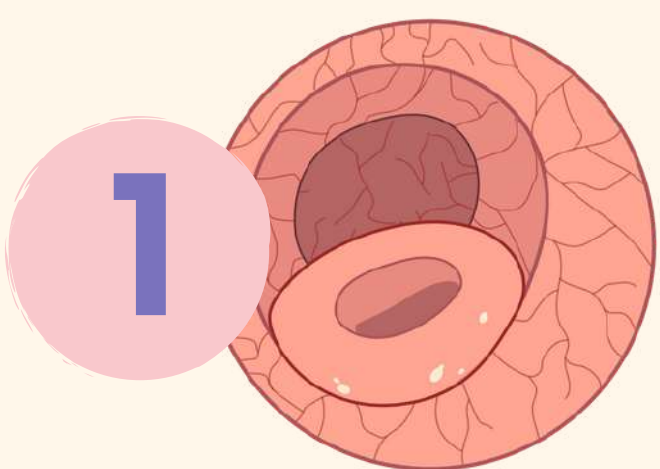


Rutgeerts endoscopic score



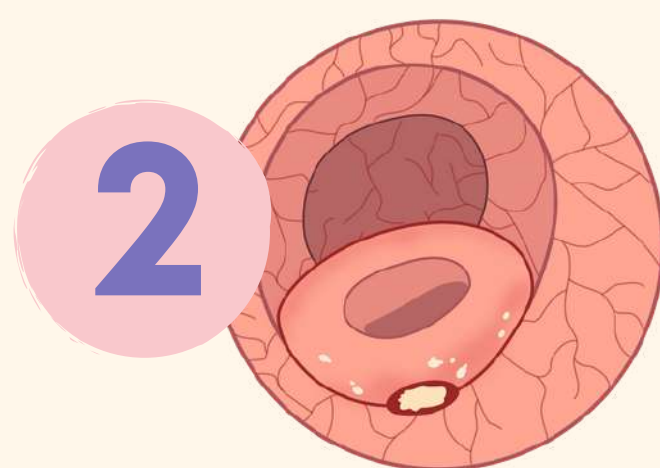
0

No lesions in the distal ileum



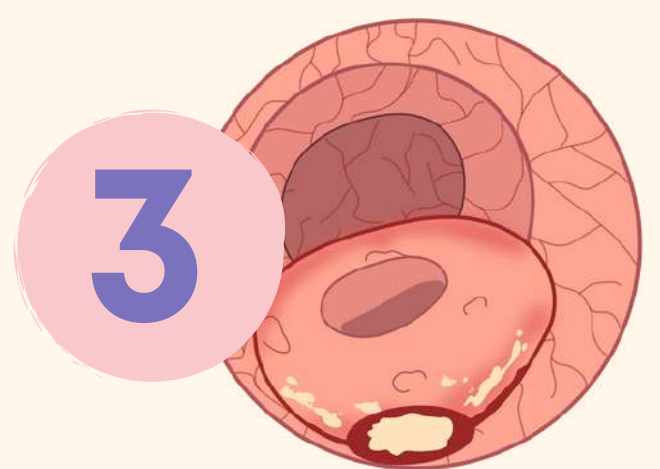
1

Not more than 5 anastomostic aphthous lesions in the distal ileum



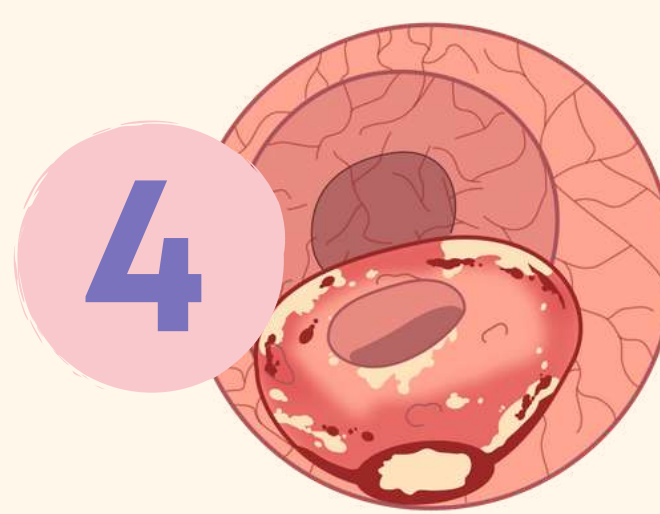
2

> 5 aphthous lesions with normal mucosa between the lesions, or skip areas of larger lesions or ulcers up to 1 cm confined to ileocolonic anastomosis



3

Diffuse aphthous ileitis with diffusely inflammed mucosa between the multiple aphthae



4

Diffuse inflammation, with larger lesions: large ulcers and/or nodules/cobble and/or narrowing/stenosis



Rutgeerts endoscopic score

Interpretation

SCORE

Post surgical

i0

Remission

i1

Remission

i2

Recurrence

i3

Advanced recurrence

i4

Advanced recurrence

