

# GEBOES score

## 0. STRUCTURAL

0

- 0 No abnormality
- 0.1 Mild abnormality
- 0.2 Mild/moderate diffuse or multifocal abnormalities
- 0.3 Severe diffuse or multifocal abnormalities

## 1. CHRONIC INFLAMMATORY INFILTRATE

1

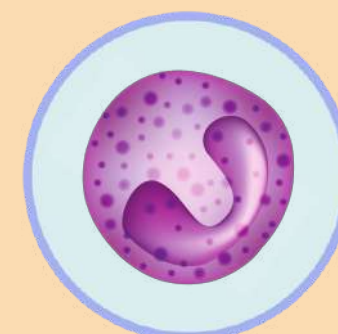
- 1 No infiltrate
- 1.1 Mild but unequivocal increase
- 1.2 Moderte increase
- 1.3 Marked increase

## 2. LAMINA PROPIA NEUTROPHILS AND EOSINOPHILS

2

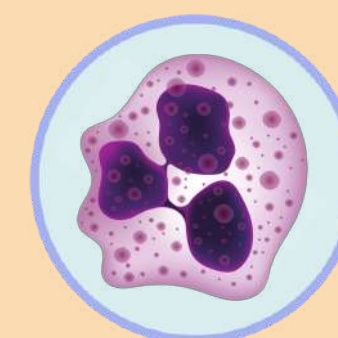
### 2A EOSINOPHILS

- 2A.0 No increase
- 2A.1 Mild but unequivocal increase
- 2A.2 Moderte increase
- 2A.3 Marked increase



### 2B NEUTROPHILS

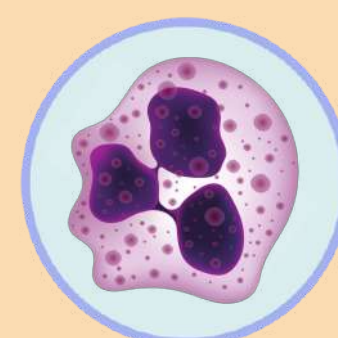
- 2B.0 None
- 2B.1 Mild but unequivocal increase
- 2B.2 Moderte increase
- 2B.3 Marked increase



## 3. NEUTROPHILS IN EPITHELIUM

3

- 3 None
- 3.1 <5% of the crypt involved
- 3.2 <50% of the crypt involved
- 3.3 >50% of the crypt involved



# GEBOES score

## 4. CRYPT DESTRUCTION

4

4.0 None

4.1 Probable local-excess of neutrophils in part of crypt

4.2 Probable marked attenuation

4.3 Unequivocal crypt destruction

## 5. EROSION OR ULCERATION

5

5.0 No erosion, ulceration or granulation tissue

5.1 Recovering epithelium plus adjacent inflammation

5.2 Probable erosion-focally stripped

5.3 Unequivocal erosion

5.4 Ulcer or granulation tissue

